CASE REPORT

Journal of Case Studies and Case Reports
An International open access, peer-reviewed, referred journal Online ISSN: 2583-4428
Content Available at www.saap.org.in Published By: South Asian Academic Publications

FAT EMBOLISM SYNDROME PRESENTING AS DIFFUSE ALVEOLAR HAEMORRHAGE: A CASE REPORT

PALANIAPPAN INBAMUTHIAH[1*], RAJESH GUPTA[1], IMAD ELDIN HAMAD[1], OSAMA ALIAN[1], SARTHY VELAYUTHAM[1], DESH DEEPAK IDNANI[2]

[1]*EHS Kuwait hospital Sharjah, UAE.*
[2]*Pure Lab Al Qasimi Hospital Sharjah, UAE.*

***Corresponding Author**
Dr Palaniappan Inbamuthiah

DOI: https://doi.org/10.37022/jcscr.v5i2.990

Article History: Received: 24 May 2026 Revised: 22 June 2026 Accepted 12 July 2026

Abstrac
Fat embolism syndrome is an uncommon complication of long-bone fractures that typically presents with respiratory distress, altered mental state and a petechial rash. Pulmonary alveolar haemorrhage is a rare manifestation. A 22-year-old Sri Lankan man sustained a right tibial shaft fracture in a motorcycle accident. He declined surgical management initially, but returned to the hospital three days later with dyspnoea, cough, a small amount of haemoptysis and chest pain. He was hypoxic (oxygen saturation 86%), tachycardic and febrile, with basal crepitations. Chest radiography showed bilateral mid and lower zone airspace opacities with ground-glass haziness. The lung infiltrates cleared almost completely within five days. Bronchoscopy was performed, and cytology of the bronchial lavage was consistent with diffuse alveolar haemorrhage, with no malignant cells or mycobacteria. This case shows that fat embolism should be considered in patients with a long-bone fracture who develop unexplained hypoxia, haemoptysis and bilateral lung infiltrates, particularly when the opacities clear rapidly. Bronchoalveolar lavage with fat staining can help to confirm the diagnosis.

Keywords: Fat embolism syndrome; Diffuse alveolar haemorrhage; Tibial fracture; Bronchoalveolar lavage; Oil red O; Haemoptysis.

This article is licensed under a Creative Commons Attribution-Non-commercial 4.0 International License. Copyright © 2026 Author(s) retains the copyright of this article.

INTRODUCTION

Fat embolism refers to the presence of fat particles in the microcirculation. Asymptomatic fat particles can be detected in the microcirculation in a significant proportion of patients with long-bone fractures [1,2], but the systemic inflammatory response that leads to fat embolism syndrome (FES) develops in only a small subset of them [3]. FES is an uncommon but potentially life-threatening complication that typically follows trauma involving fractures of the long bones (such as the femur or tibia) and the pelvis [4]. Other rare causes associated with FES include pancreatitis, bone marrow transplantation, liposuction and osteomyelitis [3]. The classical clinical presentation is a triad of respiratory distress, altered mental state and petechial rash, appearing 24 to 72 hours after a long-bone or pelvic fracture [4]. A higher number of fractures increases the incidence of FES. The incidence of FES has fallen over the past several decades because of advances in orthopaedic surgical practice and early fracture fixation [5]. With the current standard of early surgical fixation, the incidence is estimated to be between 0.9% and 11% [3]. Pulmonary alveolar haemorrhage is a rare manifestation of FES. We report a young man with a tibial shaft fracture who developed diffuse alveolar haemorrhage due to fat embolism, to highlight this unusual presentation and the diagnostic value of bronchoalveolar lavage.

CASE REPORT

A 22-year-old Sri Lankan man presented after a motorcycle accident with trauma to his right leg. Radiographs showed fractures of the proximal and mid tibial shaft. He declined surgical management and left the hospital against medical advice, opting for conservative management. Three days later he returned with dyspnoea, cough with a small amount of haemoptysis, and chest pain. On examination he was hypoxic (oxygen saturation 86%), tachycardic and febrile. Auscultation revealed basal crepitations. A chest radiograph (Figure 01) showed bilateral mid and lower zone airspace opacities with ground-glass haziness. The differential diagnoses considered were pulmonary infection, lung contusion,

pulmonary infarction and pulmonary oedema (cardiogenic or non-cardiogenic). CT angiography of the chest (Figure 02) showed bilateral lower lobe consolidation (right more than left) and nodules, with no evidence of pulmonary embolism. The patient denied any chest trauma, which argued against traumatic lung contusion.

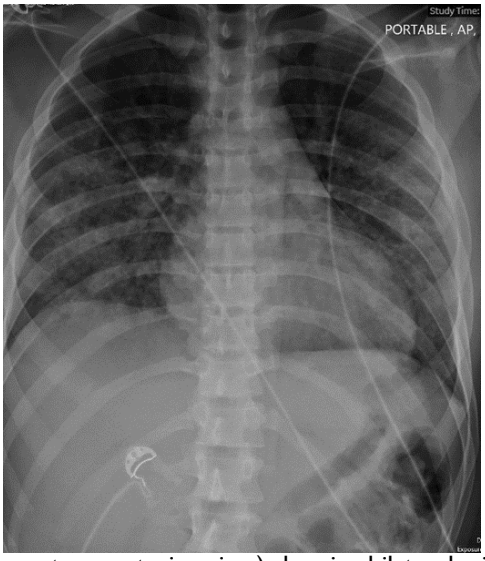

Figure 01: Chest radiograph (portable, anteroposterior view) showing bilateral mid and lower zone airspace opacities with ground-glass haziness.

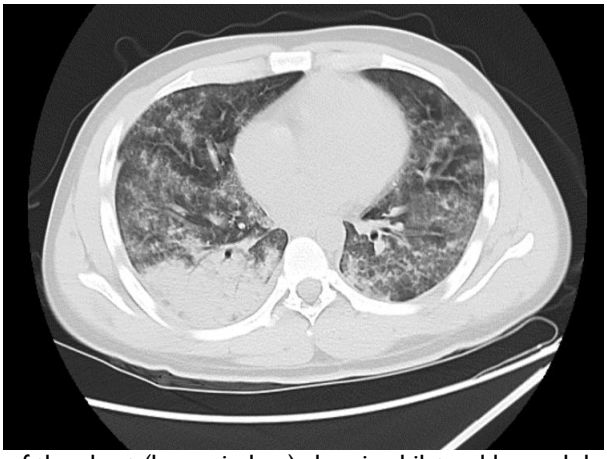

Figure 02: Axial CT angiogram of the chest (lung window) showing bilateral lower lobe consolidation, greater on the right, with nodular opacities.

Laboratory tests showed a normal white cell count, C-reactive protein of 128 and procalcitonin of 0.13. He was treated with antibiotics, and his lung infiltrates improved significantly, clearing almost completely within 5 days (Figure 3).

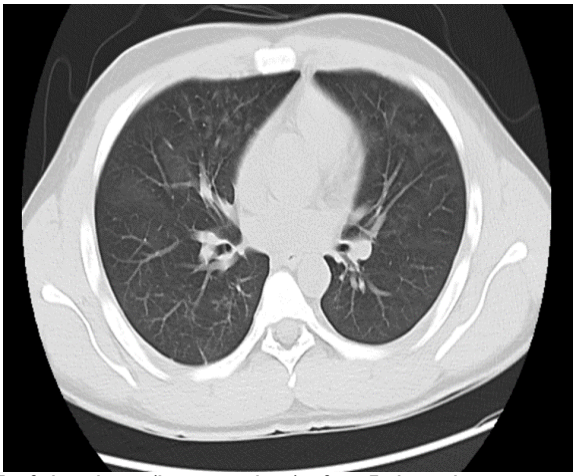

Figure 03: Follow-up axial CT of the chest (lung window) after 5 days showing near-complete resolution of the infiltrates.

Bronchoscopy was performed for diagnostic purposes. Cytology of the bronchial lavage was consistent with diffuse alveolar haemorrhage. It was negative for malignant cells, acid-fast bacilli and mycobacterial polymerase chain reaction. Given the near-complete clearing of the lung opacities within a short time and the history of a right tibial shaft fracture, fat embolism was considered. The lavage sample was stained for fat globules with Oil red O and showed fat-laden macrophages containing lipid droplets (Figure 04), which established the diagnosis of fat embolism. Lavage cytology is shown in Figure 05.

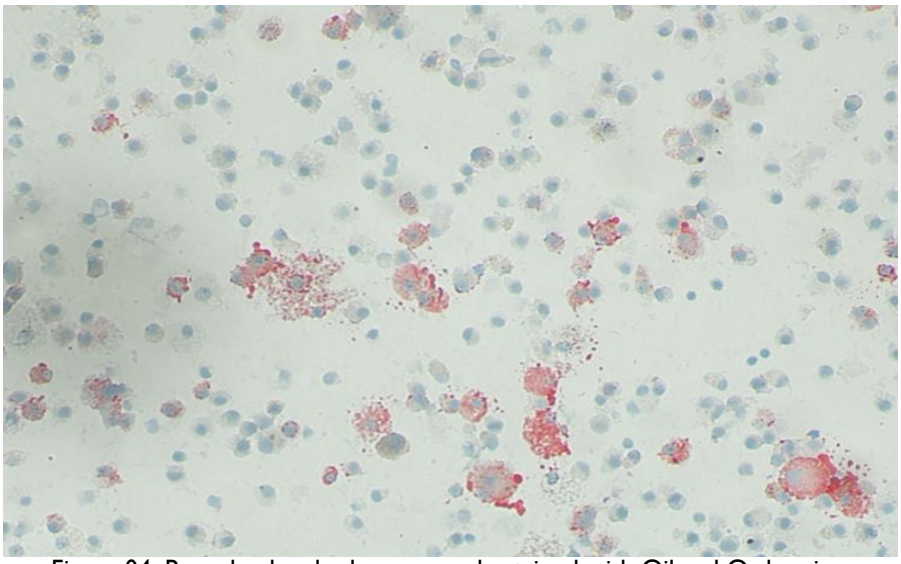

Figure 04: Bronchoalveolar lavage sample stained with Oil red O showing macrophages containing red-staining lipid droplets.

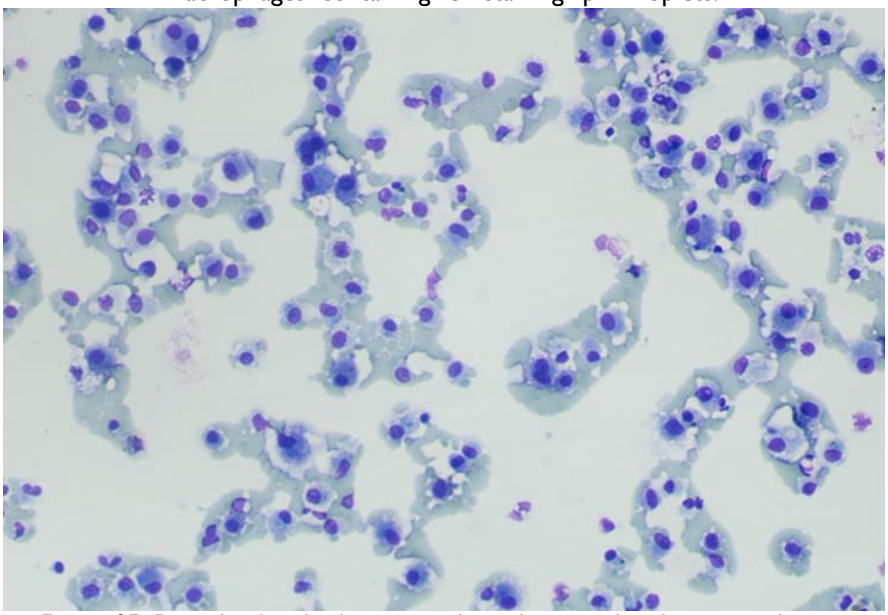

Figure 05: Bronchoalveolar lavage cytology showing alveolar macrophages.

DISCUSSION

Zenker gave the first description of FES more than 160 years ago, in a patient with a crush injury [6]. The incidence reported across studies ranges from 0.5% to 29%, and mortality from 5% to 15% [7].

Two mechanisms are proposed for the pathophysiology. In the mechanical mechanism, fat droplets from the bone marrow enter venous channels and physically obstruct the capillary beds, particularly in the pulmonary circulation. In the biochemical mechanism, embolised fat is hydrolysed into highly toxic free fatty acids, which trigger a severe systemic inflammatory cascade that damages the endothelial lining of blood vessels [8,9].

FES is a clinical diagnosis, and patients usually present within 24 to 72 hours of trauma, although onset as early as 12 hours or as late as 2 weeks has been described. Multisystem involvement may occur: pulmonary (dyspnoea, respiratory distress, hypoxia, bilateral pulmonary infiltrates, type I respiratory failure), neurological (confusion, seizures, altered sensorium), dermatological (petechial rash involving the conjunctiva, oral mucosa and skin folds of the neck and axilla)

and haematological (anaemia, thrombocytopenia, raised C-reactive protein and erythrocyte sedimentation rate, hypofibrinogenaemia). Retinal changes, such as fat globules or petechiae, can also be seen [7].

Studies have shown a strong correlation between hypoxia and free fatty acid levels in patients with major long-bone fractures, with significantly lower arterial oxygen levels in these patients [10].

The diagnosis of FES is based on history, timing of presentation and clinical manifestations, and on exclusion of other causes [11]. Various diagnostic criteria (Gurd and Wilson, Lindeque) and a scoring system (Schonfeld) have been proposed [12-14]. Elevated biological markers such as free fatty acids, lipase and phospholipase A2, and the presence of fat globules in urine or sputum, may be useful but are non-specific [4].

Pulmonary manifestations are the earliest and most common presentation of FES and occur in about 75% of patients [15,16]. They range from mild dyspnoea to rapid respiratory failure resulting from acute respiratory distress syndrome [4]. Progression to respiratory failure occurs in about 10% of patients [11]. Diffuse alveolar haemorrhage (DAH) is a rare but recognised pulmonary complication, with fewer than 20 cases reported in the literature [17-21], and it carries a higher mortality.

In our patient, hypoxia, bilateral infiltrates and haemoptysis appeared 3 days after a conservatively managed tibial fracture. The absence of pulmonary embolism on CT angiography and of any history of chest trauma argued against the other differential diagnoses. The rapid radiological clearance, the lavage findings of alveolar haemorrhage and the fat-laden macrophages on Oil red O staining supported fat embolism as the cause. Antibiotics were given, so the rapid improvement cannot be attributed to the underlying process alone. In addition, fat-laden macrophages in lavage fluid are not specific for FES, and the diagnosis therefore rests on the whole clinical picture.

CONCLUSION

Fat embolism syndrome should be considered in any patient with a long-bone fracture who develops hypoxia, bilateral lung infiltrates and haemoptysis, even when the classical features are not all present. Diffuse alveolar haemorrhage is a rare but important presentation. Exclusion of pulmonary embolism, rapid radiological clearing and bronchoalveolar lavage with fat staining help to establish the diagnosis. Because early fracture fixation reduces the incidence of FES, patients who decline surgery should be counselled about this risk and monitored closely.

ACKNOWLEDGEMENT

None

CONFLICT OF INTEREST

None

FUNDING

None

PATIENT CONSENT & ETHICAL COMMITTEE APPROVAL

Obtained as per hospital policy

REFERENCES

1. Gurd AR, Wilson RI. The fat embolism syndrome. J Bone Joint Surg Br. 1974;56B:408-16.
2. Allardyce DB, Meek RN, Woodruff B, Cassim MM, Ellis D. Increasing our knowledge of the pathogenesis of fat embolism: a prospective study of 43 patients with fractured femoral shafts. J Trauma. 1974;14:955-62.
3. Kwiatt ME, Seamon MJ. Fat embolism syndrome. Int J Crit Illn Inj Sci. 2013;3(1):64-8. https://doi.org/10.4103/2229-5151.109426
4. Luff D, Hewson DW. Fat embolism syndrome. BJA Educ. 2021;21(9):322-8. https://doi.org/10.1016/j.bjae.2021.04.003
5. Parisi DM, Koval K, Egol K. Fat embolism syndrome. Am J Orthop (Belle Mead NJ). 2002;31(9):507-12. PMID: 12650535.
6. Scuderi CS. The present status of fat embolism: bibliographic review. Int Surg Dig. 1934.
7. Singh S, Goyal R, Baghel PK, Sharma V. Fat embolism syndrome: a comprehensive review and update. J Orthop Allied Sci. 2018;6:56-63.
8. Parker FB, Wax SD, Kusajima K, Webb WR. Hemodynamic and pathological findings in experimental fat embolism. Arch Surg. 1974;108:70-4.
9. Hofmann S, Huemer G, Kratochwill C, Koller-Strametz J. Pathophysiologie der Fettembolie in der Orthopädie und Traumatologie. Orthopade. 1995;24(2):84-93. German. PMID: 7753543.
10. Nixon JR, Brock-Utne JG. Free fatty acid and arterial oxygen changes following major injury: a correlation between hypoxemia and increased free fatty acid level. J Trauma. 1978;18:23-6.
11. Shaikh N. Emergency management of fat embolism syndrome. J Emerg Trauma Shock. 2009;2(1):29-33.

12. Talucci RC, Manning J, Lampard S, Bach A, Carrico CJ. Early intramedullary nailing of femoral shaft fractures: a cause of fat embolism syndrome. Am J Surg. 1983;146:107-11.
13. Lindeque BG, Schoeman HS, Dommissen GF, Boeyens MC, Vlok AL. Fat embolism syndrome: a double blind therapeutic study. J Bone Joint Surg Br. 1987;69:128-31.
14. Schonfeld SA, Ploysongsang Y, DiLisio R, Crissman JD, Miller E, Hammerschmidt DE, et al. Fat embolism prophylaxis with corticosteroid: a prospective study in high-risk patients. Ann Intern Med. 1983;99:438-43.
15. Burger LW, Dines DE, Linscheid RL. Fat embolism syndrome and the adult respiratory distress syndrome. Mayo Clin Proc. 1974;49:107-9.
16. McCarthy B, Mammen E, Leblanc LP, Wilson RF. Subclinical fat embolism: a prospective study of 50 patients with extremity fractures. J Trauma. 1973;13:9-16.
17. Velloze S, Holtrop M, Adams TN. A case of diffuse alveolar hemorrhage secondary to fat embolism after long bone fracture. Respir Med Case Rep. 2022;39:101735.
18. Chieng H, Saha B, Foulke L, Wu GP, Chopra A. A 24-year-old man with dyspnea and a broken left femur. Chest. 2022;161(4):e225-31.
19. Petrich V, Keenan A. Diffuse alveolar hemorrhage associated with fat embolism syndrome. Chest. 2025 Oct;168:A4042-3.
20. Madabhushi A, Dean A, Alam A. A rare case of fat embolism-related diffuse alveolar hemorrhage (FEDAH). Chest. 2025 Oct;168:A4020-1.
21. Alkhazna A, Gohar A, Saeed A. Fat embolism syndrome presenting as diffuse alveolar hemorrhage. Chest. 2012 Oct;142:973A.